



Australian Society of Medical Imaging and Radiation Therapy

The national professional organisation representing medical radiation practitioners

ABN 26 924 779 836



MIAP1

July 2017

MEDICAL IMAGING ADVISORY PANEL 1

Course Syllabus

Computerised Tomography

Intermediate Level

CT Certification Course Syllabus

Introduction

The Intermediate level CT certificate is aimed at radiographers who have a minimum of 5 years full time equivalent experience in a broad range of CT examinations. In order to pass the theoretical component, candidates are expected to undertake revision of text books and other relevant literature prior to sitting the exam.

Intermediate CT certification encompasses theoretical and clinical components. In order for a candidate to apply for a 'CT Intermediate Level Certificate', the candidate must meet all of the following requirements:

1. Achieve a pass grade for the CT Intermediate Level Certification examination set by the Medical Imaging advisory Panel 1 (Part A)
2. Performed the required clinical component as outlined below (Part B)

Part A

The formal examination will involve a paper not exceeding 150 multiple-choice questions covering a range of topics (refer to the following study guide for details). The examination is divided into 4 modules. The sections and the approximate percentage* of questions related to each module is listed below:

- **PART A:** Anatomy, physiology and CT pathology - 20%
- **PART B:** Contrast agents, radiation protection and dosimetry - 20%
- **PART C:** Physical principles, hardware and artefacts - 30%
- **PART D:** CT technique - 30%

* Percentage breakdowns are an indicative value only

Part B

This clinical component requires the candidate's supervisor to acknowledge completion of the required clinical examinations (500 examinations in a 12 month period within 2 years of completing Part A). The clinical component must encompass a number of examinations from a minimum of 7 of the following examination types:

Brain	Spine	Trauma	Chest (including HRCT)	Intervention
Neck	Extremities	Paediatric	Abdomen and pelvis	Angiography

Reading material

The recommended readings are considered by MIAP1 to provide the applicant with a sound understanding necessary to complete the theoretical component and assist with additional knowledge for the clinical aspects of Intermediate CT Certification. These texts are recommended only; applicants may choose to use other sources of information.

CT texts


- DeMaio, D. N. (2011). *Mosby's exam review for computed tomography* (2nd ed.). St. Louis, Mo: Mosby Elsevier.
- Romans, L. E. (2010). *Computed tomography for technologists: Exam Review*. Baltimore, Md: Wolters Kluwer Health/Lippincott Williams & Wilkins.
- Romans, L. E. (2016). *Computed tomography for technologists: A comprehensive text*. Baltimore, Md: Wolters Kluwer Health/Lippincott Williams & Wilkins.
- Schoenhagen, P., Schultz, C. J., & Halliburton, S. S. (2014). *Cardiac CT made easy: An introduction to cardiovascular multidetector computed tomography* (Second ed.). Boca Raton: CRC Press/Taylor & Francis.
- Seeram, E. (2016). *Computed tomography: Physical principles, clinical applications, and quality control* (Fourth ed.). St. Louis, Missouri: Elsevier.

Anatomy texts

- Anderson, M. W., Fox, M. G., & El-Khoury, G. Y. (2017;2016;). *Sectional anatomy by MRI and CT* (Fourth ed.). Philadelphia, PA: Elsevier.
- Ellis, H., Logan, B. M., & Dixon, A. K. (2015). *Human sectional anatomy: Atlas of body sections, CT and MRI images* (4th ed.). Hoboken: CRC Press.
- Lazo, D. L. (2015). *Fundamentals of sectional anatomy: An imaging approach* (Second ed.). Stamford: Delmar.

Websites

- RANZCR guidelines for iodinated contrast. Available from: <http://www.ranzcr.edu.au/resources/professional-documents/guidelines>
- Radiopaedia. Available from www.radiopaedia.org



Journal articles (free full text online)

- Halliburton, S., Arbab-Zadeh, A., Dey, D., et al. (2012). State-of-the-art in CT hardware and scan modes for cardiovascular CT. *Journal of Cardiovascular Computed Tomography*, 6(3), 154-163. doi:10.1016/j.jcct.2012.04.005
- McCollough, C. H., Leng, S., Yu, L., & Fletcher, J. G. (2015). Dual- and multi-energy CT: Principles, technical approaches, and clinical applications. *Radiology*, 276(3), 637-653. doi:10.1148/radiol.2015142631


Please refer to Medical Imaging Advisory Panel 1 (MIAP1) Policies & Procedures Manual for up to date information on CT Intermediate Level Certification (Part A). This document can be found at: <http://www.asmirt.org/ct.php> .

Examination success

CT Experience- this exam is not designed for candidates who have spent less than 5 years in a CT room. You are not precluded from sitting the examination but past results have shown that it is extremely difficult to pass without significant hands on CT experience.

Study period- A pass in this examination is dependent on a well-designed and lengthy study program. Successful candidates have recommended a minimum of 6 months concentrated study.

Mentors- successful candidates have involved their work colleagues, previous successful candidates and a mentor. It is also recommended to use study material that contains MCQ's or review questions. There is no requirement to answer the section in any particular order, e.g. some candidates suggested answering the section that you are most familiar with first.



Section A: Anatomy, physiology and CT pathology

Applicants will be expected to be able to identify the following structures on standard CT images (including coronal, sagittal 3D and CT angiography images where applicable) and/or line drawings. Applications will also be expected to have a basic knowledge of the spatial relationships of these structures.

Head

- Skeletal structures: sella turcica, foramen magnum, air sinuses (frontal, ethmoid, sphenoid), mastoid air cells, IAM, EAM, jugular foramen, carotid canal
- Arteries: vertebrals, basilar, internal carotids, posterior inferior cerebral artery, anterior and poster communicating arteries, and middle, anterior and posterior cerebrals
- Venous system: cavernous sinus, superior sagittal sinus, straight sinus, transverse sinus, internal jugular veins, confluence of sinuses
- Intra- cerebral ventricular system: lateral 3rd and 4th ventricles, choroid plexus, ambient (quadrigeminal) and basal (interpeduncular) cisterns
- Meninges: falx, tentorium cerebelli
- Cerebrum and cerebellum: pons, lobes (frontal, temporal, parietal, occipital) fissures (sylvian fissure, longitudinal fissure, central sulcus), corpus callosum, pituitary and pineal glands, thalamus, head of caudate nucleus, internal capsule, lentiform nucleus.

Neck/face

- Skeletal structures: maxillary sinuses, hyoid bone, styloid process
- Arteries: common carotid, internal carotid, external carotid, vertebral, subclavian, brachiocephalic
- Veins: internal and external jugular, subclavian, brachiocephalic
- Airway structures: cricoid cartilage, thyroid cartilage, epiglottis, pharynx, oesophagus, piriform fossa,
- Glands: thyroid, submandibular, parotid
- Muscles: Platysma, sternocleidomastoid, trapezius

Chest

- Skeletal structures: ribs, sternum
- Arteries: aorta, brachiocephalic, subclavian, pulmonary trunk
- Veins: IVC, SVC, subclavian, brachiocephalic, pulmonary, azygos
- Heart: atria, ventricles, pericardium, valves, arteries: left main, left anterior descending, right coronary, circumflex
- Airways: trachea, bronchi, carina



- Lungs: lobes, fissures, pleura

Abdomen

- Skeletal structures: pelvis, scrum, coccyx
- Arteries: abdominal aorta, celiac, SMA, renal, iliac, femoral
- Veins: IVC, renal SMV, portal, iliac, femoral, hepatic
- Organs: liver (gall bladder, common bile duct, other bile ducts), kidneys, adrenals, pancreas, spleen, bladder, ureters, prostate, seminal vesicles, uterus, ovaries
- GI tract: oesophagus, stomach, duodenum, colon, ovaries, seminal vesicles
- Muscles: psoas, quadratus lumborum, iliacus, transversus abdominus, rectus femoris

Spine

- Vertebral bodies, foramen, processes, articular surfaces, intervertebral discs, nerves

Physiology

- CSF production, circulation and absorption
- Cardiovascular circulation
- Portal venous blood supply

PATHOLOGY

Head

- Hemorrhage: subdural, extra-dural, sub-arachnoid, intra-cerebral
- Hydrocephalus
- Infarct (stroke)
- Space-occupying lesion

Neck/face

- Sinusitis
- Goitre
- Lymphadenopathy

Chest

- Pneumothorax
- Emphysema
- Infective disease
- Lymphadenopathy



- Bronchiectasis
- Pulmonary embolus

Abdomen

- Laceration of solid organs
- Hemangioma
- Renal/liver cyst
- Renal calculus
- Appendicitis
- Psoas abscess
- Pancreatitis
- Lipoma
- Ovarian cysts

Spine

- Trauma
- Disc herniation

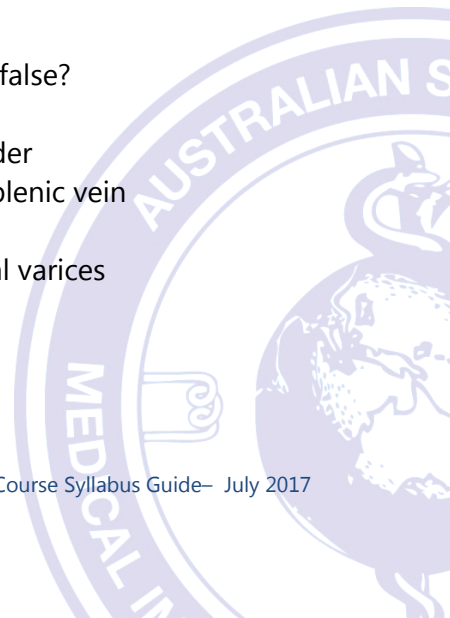
SAMPLE QUESTIONS

- 1) The lateral ventricles of the brain are connected to the third ventricle by which of the following structures?
- A. Ambient cistern
 - B. Cerebral aqueduct/Aqueduct of Sylvius
 - C. Interventricular foramen/Foramen of Monro
 - D. Foramen of Lushka

Answer: C

- 2) Which of the following statements about the portal venous system is false?
- A. It drains blood from the bowel, spleen, pancreas and gallbladder
 - B. The portal vein is formed by the joining of the SMV and the splenic vein
 - C. The portal venous system transports blood directly to the IVC
 - D. Portal hypertension can result in the formation of oesophageal varices

Answer: C



- 3) A differential diagnosis of a haemangioma of the liver can be made from a multiphase scan of the liver if:
- A. The lesion appears denser during the delayed phase than during the arterial or portal venous phase
 - B. The density of the lesion does not change with different phases of contrast enhancement
 - C. The lesion is less than 3cm in size
 - D. The lesion shows no enhancement in the arterial phase

Answer: A



Section B: Contrast agents, radiation protection and dosimetry

Contrast agents

- Pharmacology: Ionic vs non-ionic contrast, monomer versus dimer, viscosity, strength, osmolality, chemical structure
- Contraindications for oral and intravenous contrast agents
- Possible side effects
- Immediate treatment for contrast reactions
- Contrast-induced renal nephropathy: patients at risk, precautions
- Allergic-type reactions: patients at risk, precautions
- Use in pregnancy in lactation
- Administration routes
- Indications for use
- RANZCR guidelines on contrast administration

Radiation protection and dosimetry

- CT dose parameters: CTDI, DLP, effective dose
- Australian DRLs for routine CT of the head, neck, chest and abdomen
- Approximate effective doses for routine CT of the head, chest and abdomen
- Technical factors that influence patient dose
- The use of CT during pregnancy
- Special needs for paediatric patients
- Dose minimization techniques

SAMPLE QUESTIONS

- 1) Which of the following interactions between x-ray photons and matter results in the largest amount of patient dose?
- A. Characteristic
 - B. Compton scatter
 - C. Bremsstrahlung
 - D. Photoelectric effect

Answer: D



2) Examples of mild adverse reactions to iodinated intravenous contrast media may include:

1. Nausea
2. Dyspnea
3. Warm, flushed sensation

- A. 1 only
- B. 1 & 2 only
- C. 1 & 3 only
- D. 2 & 3 only

Answer: C



Section C: Physical principles, hardware and artefacts

Terminology

- Pitch
- Hounsfield unit
- Pixel
- Algorithm/kernel
- Interpolation
- Window width and window level
- Image filter
- Display field of view
- Scan field of view

Image quality and quality assurance

- Noise
- High contrast resolution
- MTF
- Low contrast resolution
- Linearity
- Uniformity
- Cupping

Scanner hardware and technology

- Detector configurations
- Beam filtration
- Scanner configurations
- MSCT vs single slice
- Helical vs axial

Artefact

- Beam hardening
- Partial volume artefact
- Motion artefacts
- Calibration error
- Metal artefacts
- Zebra artefacts
- Windmill artefacts



3D reformatting techniques

- Surface shaded display
- Volume rendered display
- Maximum intensity projection
- Multiplanar reformation

Special techniques

- Cardiac CT: prospective vs retrospective gating, step-and-shoot mode vs helical mode
- CT brain perfusion: acquisition modes: shuttle/helical/wide volume, reporting parameters: mean transit time (MTT), time to peak (TTP), cerebral blood volume (CBV), cerebral blood flow (CBF), penumbra vs ischaemia
- Dual energy: acquisition modes (dual detector layer, kVp switching, dual tube, two acquisitions)

SAMPLE QUESTIONS

- 1) Increasing the scan field of view:
- A. Increases the number of detector cells collecting data
 - B. Increases the range of HU displayed on the image
 - C. Decreases the pixel size
 - D. Decreases the display field of view

Answer: A

- 2) A CT slice is taken with the following factors: mA = 300, scan time = 1 second, matrix = 512, kVp = 120, slice thickness = 5mm. The resulting image is suspected of containing a considerable amount of volume averaging. Which of the following factors is primarily responsible?
- A. mA
 - B. Scan time
 - C. Matrix
 - D. Slice thickness

Answer: D



3) A grid formed from columns and rows of pixels is called a?

- A. Back projection
- B. Convolution filter
- C. Matrix
- D. Histogram

Answer: C



Section D: CT technique

- Effect of acquisition and reconstruction parameters on image noise and high contrast resolution
- Effect of scan acquisition parameters on patient dose
- Helical vs non helical: indications for use, advantages and disadvantages of use
- Technique modification for paediatrics, trauma, patient size
- Contrast timing: available timing techniques, approximate scan delays for arterial, portal-venous, nephrogram and pancreatic phases

Routine image techniques for the following examinations:

- Head (routine)
- Inner ear
- Sinuses
- Face (trauma, infection, tumour)
- Neck
- Thorax (routine, HRCT, pulmonary)
- Abdomen: routine, multiphase liver, multiphase pancreas, multiphase kidney, renal colic
- Spine (including trauma)
- Extremities (including trauma)

CT angiography for the following:

- Brain
- Neck
- Chest (including CT pulmonary angiography)
- Abdomen and pelvis
- Lower limb

Special techniques (basic theoretical understanding)

- Cardiac CT angiography: patient preparation, indications , systolic vs diastolic acquisition, helical vs step-and-shoot mode
- Cardiac calcium score: indications, acquisition
- Brain perfusion: indications
- CT colonography
- Dual energy:



SAMPLE QUESTIONS

1) The technique used in obtaining high resolution CT (HRCT) includes:

- A. Thin collimation
- B. Utilising a high spatial frequency algorithm or filter
- C. Increased technical factors (kVp and mAs)
- D. All of the above
- E. A & B only

Answer: E

2) The non-equilibrium phase of the liver usually occurs how long after the commencement of the injection?

- A. 55-120 seconds
- B. 2 minutes
- C. 3-4 minutes
- D. 3-4 hours

Answer: A

3) The adrenals should be included on a routine oncology chest scan because

- A. Lung may be seen below the adrenal glands
- B. Lung is never seen below the adrenal glands
- C. Adrenal glands enlarge with infection
- D. Lung tumours can metastasize to the adrenals

Answer: D

